

The Additional Diagnostic Value of the Three-dimensional 3D ultrasound and Doppler angiography imaging in the prenatal diagnosis of left isomerism

Wael El Guindi^{1,*}, Michel Dreyfus², Gabriel Carle¹, Nidal Alassas³

¹Department of Obstetrics and Gynecology, Franck Joly Hospital, Saint-Laurent-du-Maroni, France

²Department of Obstetrics and Gynecology, Caen University Hospital, Caen, France

³Department of Obstetrics and Gynecology, CHI Redon-Carentoir, France

Abstract

Objective

To highlight the value of 3D ultrasound and Doppler angiography imaging in the prenatal assessment of left fetal isomerism.

Methods

A retrospective offline analysis of volume datasets of 3 fetuses with left atrial isomerism by 3D ultrasound was conducted.

Conclusion

We believe that parasagittal view demonstrating the heart and the abdominal vessels is easy to obtain and interpret, offer a realistic anatomic image, needs no mental reconstruction of spatial relationships and is very beneficial mainly in detecting the situs. We propose to use 3D ultrasound systematically in suspected cases of atrial isomerism, and better understand and interpret fetal anatomy.

Corresponding author: Wael El Guindi, Department of Obstetrics and Gynecology, Franck Joly Hospital, Saint-Laurent-du-Maroni, France, 17 Voies des Saules 94310. Orly. Paris, Tel.: 0774253858

Citation: Wael El Guindi, Michel Dreyfus, Gabriel Carle, Nidal Alassas (2020) The Additional Diagnostic Value of the Three-dimensional 3D ultrasound and Doppler angiography imaging in the prenatal diagnosis of left isomerism. Journal of Clinical Case reports and Images - 2(1):9-21. <https://doi.org/10.14302/issn.2641-5518.jcci-20-3636>

Keywords: Heterotaxy; Isomerism; Polysplenia; Asplenia; Situs ambiguus; Situs inversus; Situs solitus, Cardiovascular malformations, Power Doppler imaging, 3D ultrasound. Left atrial isomerism. Malrotation.

Received: Nov 28, 2020

Accepted: Dec 12, 2020

Published: Dec 16, 2020

Introduction

At very early embryonic stages the embryo appears symmetrical with respect to the midline [1] During gastrulation, this initial symmetry is broken by cascades of gene activation that confer specific properties on the left and right sides of the embryo. This step, symmetry breaking; is essential for proper establishment of a predictable left-right (LR) patterning and placement of the internal organs and associated vasculature. [2, 3]. This left-right (LR) asymmetry arise much earlier than the morphological asymmetry of visceral organs and is fundamental to their function and position within the body. [2].

The term situs solitus is used to describe the usual asymmetric positioning of the cardiac atria and the viscera. Defects in LR asymmetric patterning often leads to malformations, including heterotaxy syndromes [4,5,6]. (derived from the Greek heteros, "other" and taxis, meaning "arrangement meaning other than the usual arrangement") which is also named situs ambiguous, isomerism, asplenia and polysplenia syndromes. Here, the pattern of spatial organization of the thoracic and abdominal organs demonstrates abnormal arrangement across the left-right axis of the body i.e. neither the normal (situs solitus) nor mirror image arrangement (situs inversus). [7]. There is not one specific finding that is pathognomonic for situs ambiguous (heterotaxy) but rather there is a combination of findings seen in situs solitus and situs inversus. [9,10].

Heterotaxy syndromes are conventionally grouped in two categories defined according to the status of the spleen and the morphology of the atrial appendages, bronchi, and lungs into the subsets of asplenia syndrome or right isomerism, and polysplenia syndrome, also known as left isomerism. [9, 10,11]. The distinction between the two groups is based on the common concurrence of different abnormalities found with this disorder. The polysplenia syndrome is usually observed in patients with bilateral left sidedness, a condition in which both lungs resemble the left lung. The asplenia syndrome may be associated with a bilateral right sidedness, a condition in which both lungs morphologically resemble the right lung. [9,10,11,12]. The relation between left isomerism

and polysplenia, right isomerism and asplenia is close, but not one to one, a spleen can be found in right isomerism, just as the spleen can be absent with left isomerism.[12]. This classification may provide a helpful starting point for a mental organization that allow the clinician to predict structural and physiological abnormalities based on patterns but they are not the rule. [12] Due to morphological variability within the cases, there is no single classification that encompasses the wide spectrum of findings found with this disorder. On account of that, some clinicians advocate referring to it as left atrial isomerism followed by a specific description. [13]. We present four cases diagnosed in our department in a period of 16 months. With these four cases and a review in the literature, we explore the definitions and characteristics of left atrial isomerism and we provide a new diagnostic tool of fetal situs anomalies.

Materials and Methods

We present 4 cases diagnosed with left atrial isomerism in our department in a period of 16 months. With these 4 cases and a review in the literature, we explore the definitions and characteristics of left atrial isomerism and we highlight the value of 3D ultrasound in the prenatal assessment of atrial isomerism syndromes.

Examinations were performed via Voluson 730 Pro (General Electric, Milwaukee, WI, USA) with a volumetric abdominal transducer (4–8 MHz). Stored cardiovascular volumes were prospectively and subsequently analyzed offline. Volume datasets were evaluated by an independent examiner who was not blinded to the previous diagnoses of cardiac anomalies per 2D ultrasound. Sonography images were then sent via the internet to a diagnosis reference center (Caen Teaching Hospital, France), and prenatal the initial diagnosis was confirmed or revised. A multidisciplinary team—including a pediatric cardiologist, a neonatologist, and a pediatric cardiac surgeon provided comprehensive prenatal counseling to each expectant mother. Neonatal echocardiography was used to confirm the prenatal diagnosis in surviving fetuses.

Results

In our study, three patients had an interruption of the IVC (figure 2 b, c), the first patients had severe

cardiac malformation and 2 patients had a persistent left superior vena cava (LPSVC) (figure 4 a, b). The four patients had ultrasonographic signs for situs ambiguous (left isomerism) and in 3 of them the diagnosis was confirmed by fetopathological examination. The first patient had an unfavorable outcome (pregnancy termination "hydrops foetalis") and this was linked to severe heart disease. The second case with no severe cardiac malformation delivered at 27+6 weeks' gestation and child had psychomotor retardation which appears to be related to extreme prematurity. All the three karyotypes were normal, research 22q11 microdeletion was negative. " Double vessel sign " was found in all cases with interruption of the IVC with azygos continuation -VCI. (Figure 3 b, c). Grayscale facilitated the diagnosis of situs (Figure 1). Power Doppler imaging contributed primarily to prenatal diagnosis of vascular anomalies, and it was beneficial in detecting situs (Figure 2). 3D ultrasound and Doppler enhanced the visualization of fetal vessels. Using volumes, meticulous offline evaluation can be performed, enabling the operator to reconstruct fetal anatomy. 2 patients had the stomach in the right side, one of them without congenital heart disease. (figure 1 d , 3b).

One patient had dextrocardia in which the diagnosis was evoked by Doppler imaging following localization of the apex of the heart and axis of the left hepatic vein on opposite sides, both left hepatic vein (LHV) and the apex of the heart are in the same side and point to the same direction i.e. downwards, the cardiac apex points to an opposite direction with respect to the spine i.e. away from the spine. (figure 2d). In levocardia the cardiac apex is oriented away from the spine, on the other hand, in dextrocardia, the cardiac apex is oriented toward the spine (figure 2). The 4 patients had a liver in the median position , one patient had the appendix and gall bladder (*white asterisk*) are on the left side, rectosigmoid is on the right side.(figure 1 a,b,c,d,f). And another patient had intestinal nonrotation, the entire small bowel localizing to the right abdomen and colon localizing to the left abdomen. (figure g,h). One patient had congenital duodenal obstruction caused by Ladd's bands (figure 1 I,j)

Discussion

The earliest recorded example of a case of asplenia with a malformed heart that of Martin in 1828. [15]. Biron Ivemark noted the association of spleen anomalies with some cardiac malformations like atrioventricular canal defects and conotruncal anomalies, he published in 1955 in Acta Paediatrica his landmark paper which included analyses of all cases in the published literature as well as his own 14 cases , this paper was one of the first to recognize the association between splenic status, complex congenital cardiac disease, and abnormal arrangement of the viscera, focusing on the tendency to symmetry, and his name is linked as "Ivemark's syndrome" with this constellation of anomalies [10,15,16]. Polhemus recognized that asplenia and polysplenia were associated with complex congenital heart disease. [17]. Polysplenia was overlooked as a marker of HS until Moller and his colleagues in 1967 first fully documented the polysplenia syndrome, in their breakthrough paper they correlated their own findings with the literature and showed the relation between polysplenia and bilateral left-sidedness syndrome. [15,18]. Van Mierop et al. emphasized the association between asplenia and bilateral right sidedness [19,20]. Putschar and Mannion referred to a 'symmetrical situs' that sometimes exists, exhibiting symmetrical rightness or leftness on both sides. Although terminology has evolved, this is probably the most eloquent description of isomerism in the historical literature. Van Praagh regrouped these cardiac malformations into 2 groups, those that are more frequent with asplenia (right isomerism) and those that are more associated polysplenia (left isomerism).

Van Mierop [19] described the concept of the left and right atrial isomerism that was not universally accepted. [22]. Van Praagh et al. [24] have pointed out that the concept of bilateral or two right atria and bilateral or two left atria is anatomically unrealistic because atrial chambers as a whole are not entirely isomeric [10] , so this concept of atrial isomerism was refined to the right and left atrial appendage isomerism by McCartney and Anderson [25]. Of note, true isomerism of the atrial appendages (considered in isolation) has been demonstrated previously. [26]. Therefore, the concept of isomerism of the right and left

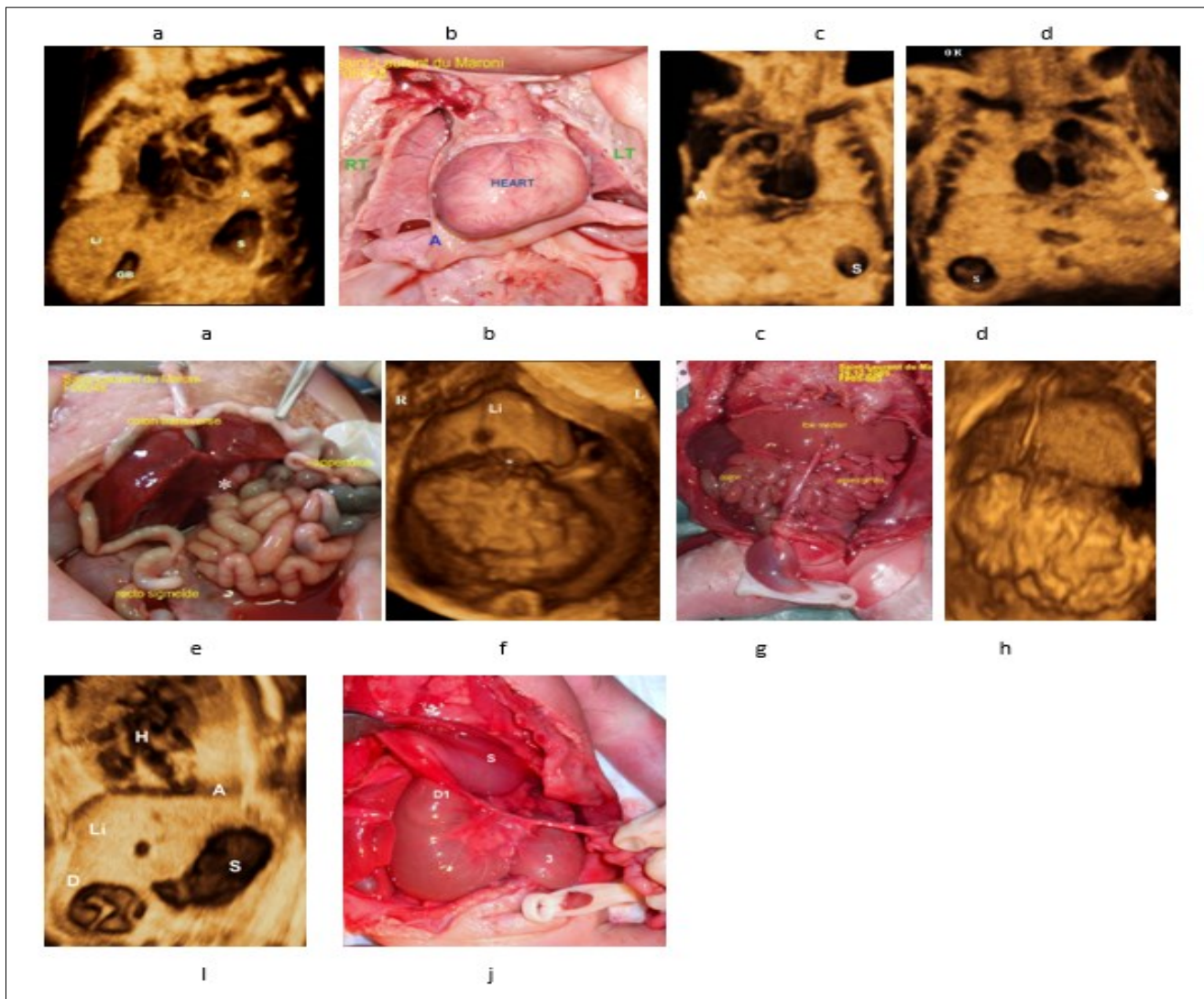


Figure 1. a-Case control, 3D volume of normal situs solitus (28 weeks' Gestation). The heart and stomach are on the left; the gallbladder is on the right, liver is predominantly on the right side.

b,c- Dextrocardia , echo-anatomic correlation.

d- Stomach are on the right side , Apex of the heart is on the left.

e,f) Liver in the median position (echo-anatomic correlation), appendix and gall bladder ((white asterisk) are on the left side, rectosigmoid is on the right side.

g -Nonrotation , the entire small bowel localizing to the right abdomen and colon localizing to the left abdomen.

h- Liver in the median position (echo-anatomic correlation with g).

i-Grey scale frontal view, showing the characteristic "double-bubble" appearance of the stomach and duodenum, note that the apex of the heart is toward the stomach i.e. left side.

j- (echo-anatomic correlation with i) D1 first part of duodenum , S stomach , *** Ladd's bands (cause of obstruction).

A: Apes of the heart S: Staomach R: Right L: Lefi Li: Liver . H: Hand denting apex of the heart GB: Gall Bladder.

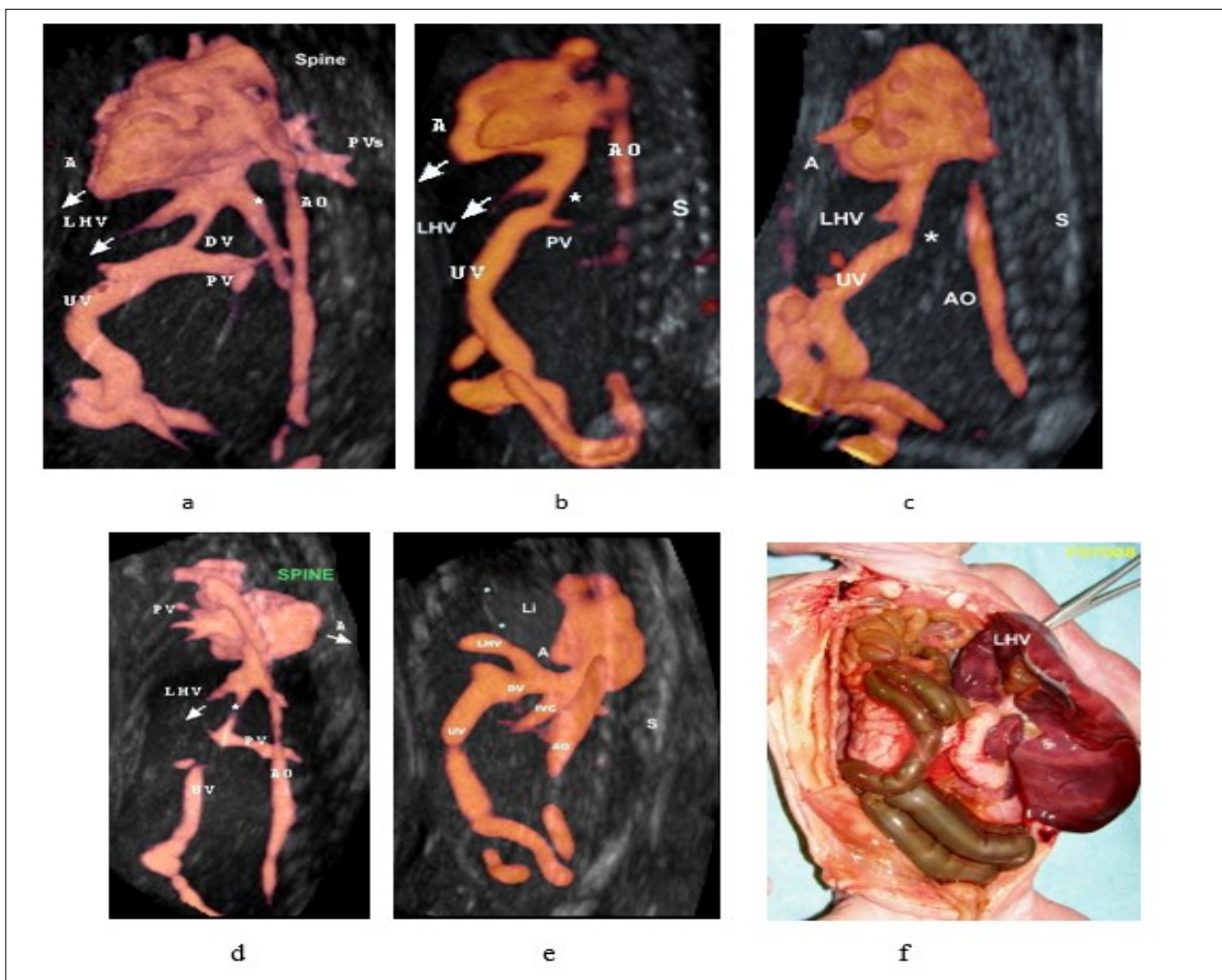


Figure 2. Three-dimensional ultrasound in glass body mode of a parasagittal view

(a) normal venous anatomy, the umbilical vein joins the IVC via ductus venosus and hepatic veins drain into the IVC, The IVC then enters the right atrium, the apex of the heart, and the left hepatic vein are on the same side. cardiac apex points toward the spine (dextrocardia).

b,c) fetus with left isomerism and interrupted inferior vena cava with azygos continuity. The inferior vena cava is not identified (location marked by the asterisk).

d) The apex of the heart and the left hepatic vein are on opposite sides (arrows), cardiac apex points toward the spine (dextrocardia).

(e) The left hepatic vein is directed toward the thorax "liver up" in a case of left diaphragmatic hernia – confirmed by fetopathological examination (f). Case control.

(f) Fetopathological examination showing "liver up" (echo-anatomic correlation). Note that left hepatic vein is directed toward the thorax

Note that in normal anatomy, the apex of the heart, and the left hepatic vein are on the same side.

Abbreviations: A, apex of the heart; AO, aorta; AZ, azygos vein; CS, coronary sinus; DV, ductus venosus; LHV, left hepatic vein; LSV, left superior vena cava; PLSV, persistent left superior vena cava; PV, portal vein; PVS, pulmonary veins; RA, right atrium; RSVC, right superior vena cava; SVC, superior, S : spine . St: stomach. T, thorax; UV, umbilical vein. IVC : inferior vena cava

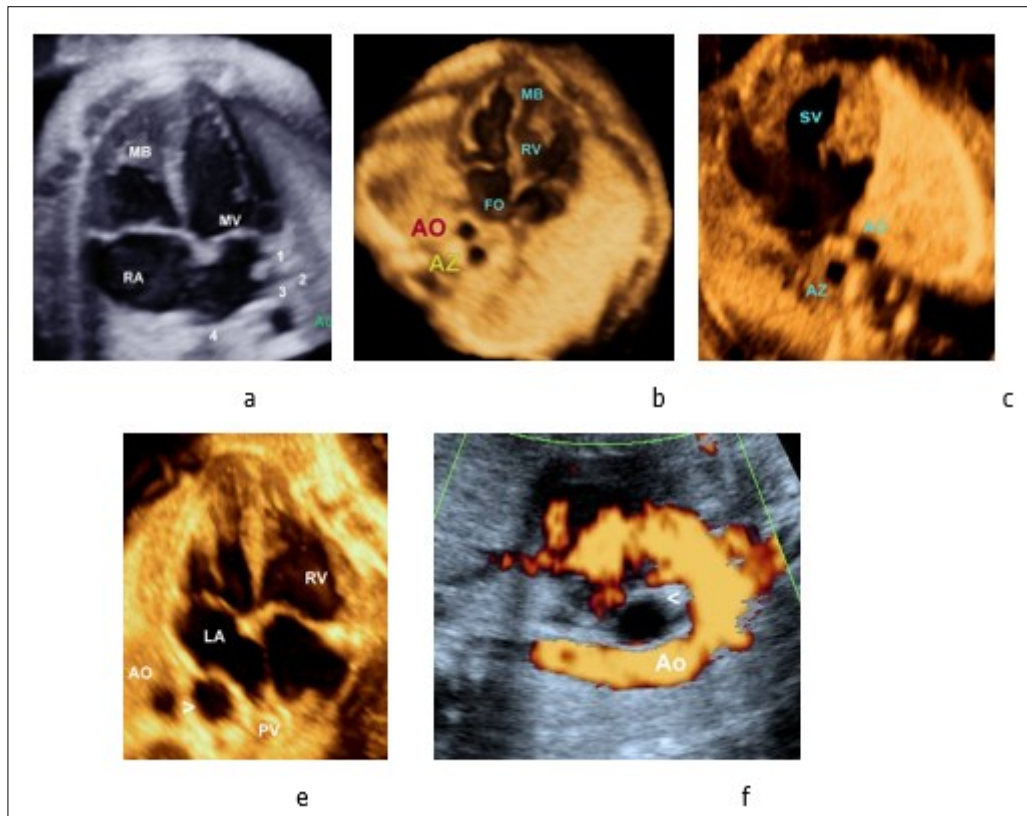


Figure 3.

Four-chamber views in four fetuses:

a- Normal cardiac anatomy

b- Normal cardiac anatomy and left atrial isomerism

c-Complex cardiac malformation (AVC) with left atrial isomerism (B).

Note the presence of double vessels in front of the spine in both fetuses (the azygos vein [AzV] and the descending aorta [AO]), which suggests interrupted inferior vena cava and left isomerism in both fetuses

d- Axial view of the fetal thorax showing the 4-chamber view of the heart and the distended esophagus (*arrowhead*). Esophageal duplication cyst that can be confound with a dilated Azygos vein, color doppler differentiate between them. Case control.

Abbreviations

MD, Moderator Band RV, right ventricle; LV, left ventricle RV, right ventricle; LA, left atrium; Ao, aorta.

Az,Azygos vein AVC, Atrio-ventricular Canal.

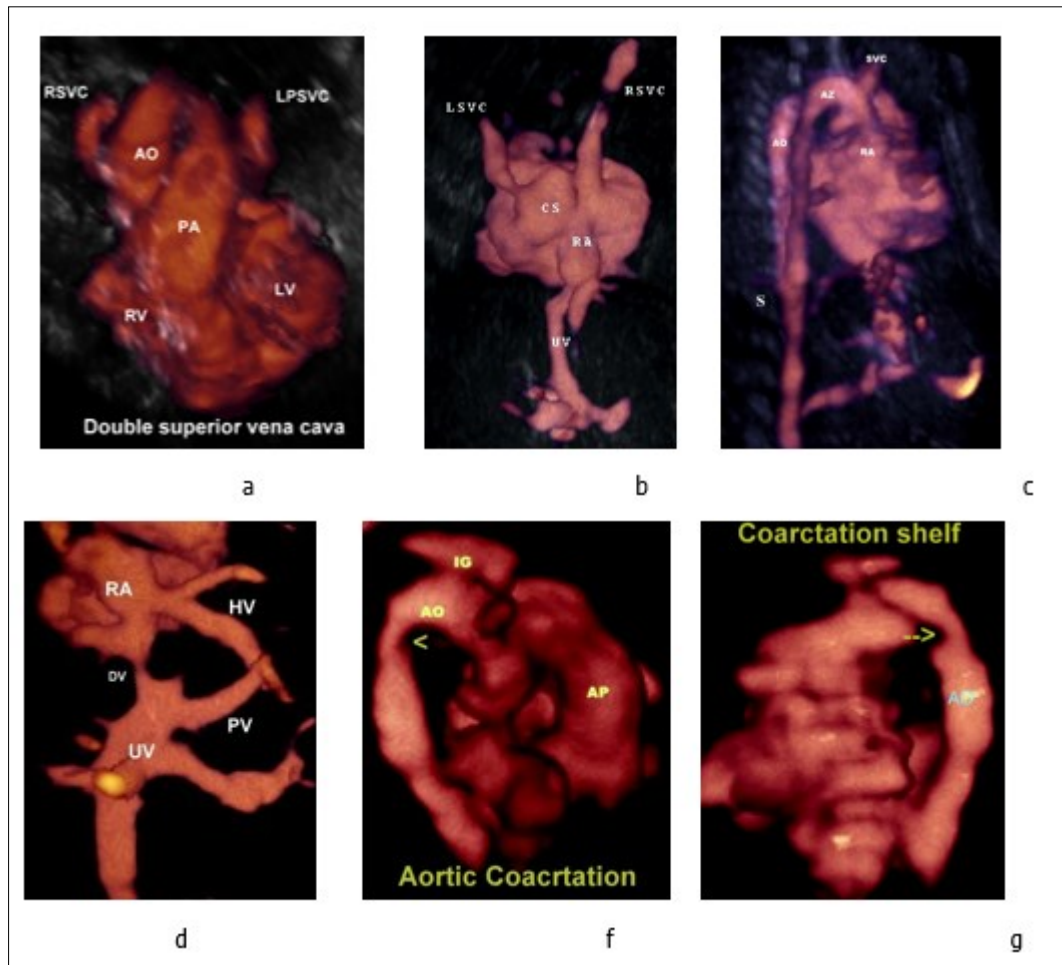


Figure 4.

a-Three-vessel-trachea view showing the persistent left superior vena cava located left of the pulmonary artery.

b-Persistent left superior vena cava draining into the dilated coronary sinus and to the right atrium, the coronary sinus is aneurysmal

c-Three-dimensional ultrasound in glass body mode showing the Azygos vein and Aorta

d- Anomalous hepatic venous drainage directly into the right atrium.

e, f- Aortic coarctation (arrow head), note the presence of coarctation shelf (arrow).

Abbreviations

RA: right atrium AO: aorte UV: umbilical vein AP : Pilmonary artery PV: Portal vein
DV : Ductud venosus

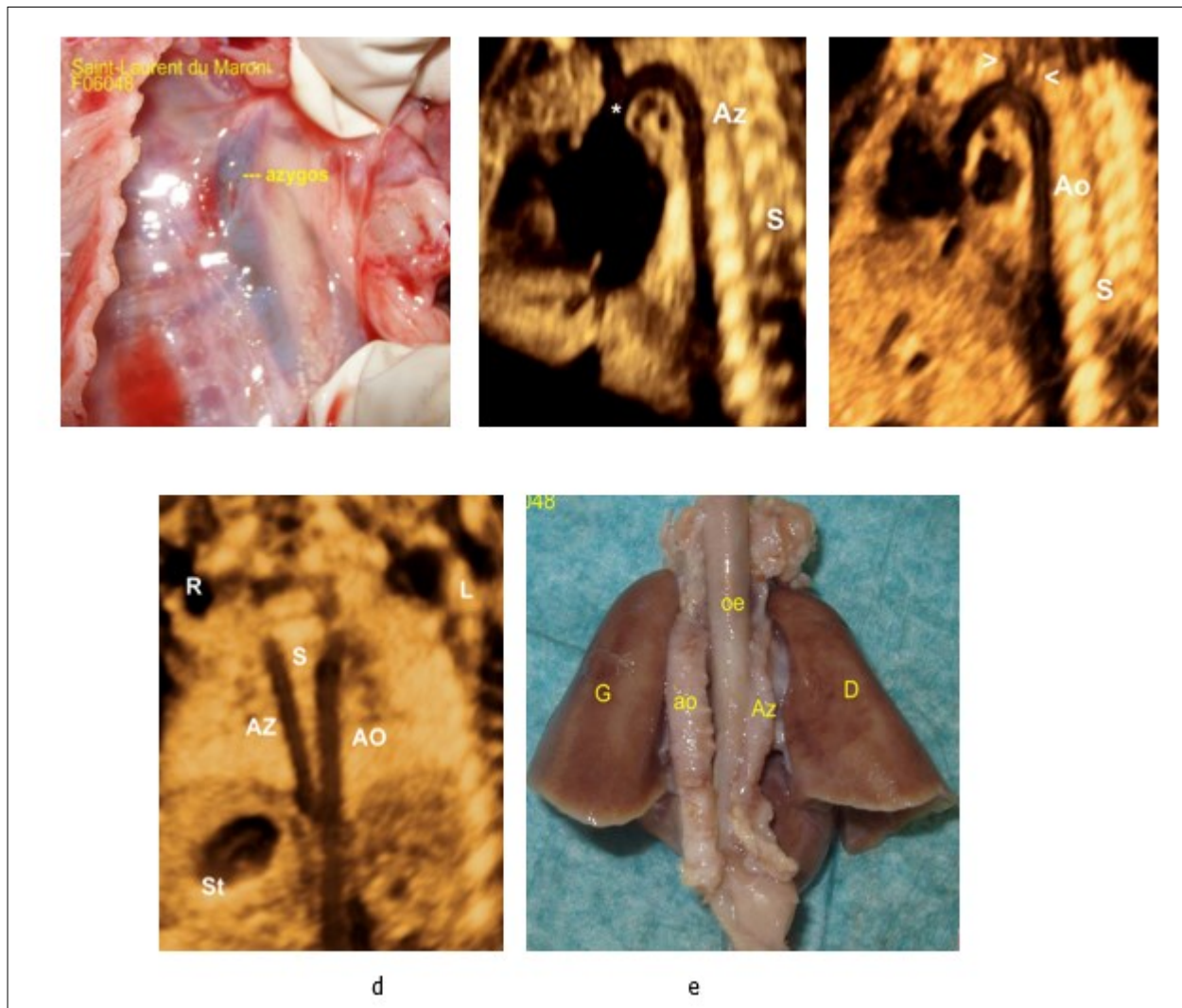


Figure 5.

a-Fetopathological examination showing dilated azygos

b- Sagittal image demonstrating the dilated azygos vein and azygos arch connecting to the superior vena cava (*).

c-Aortic arch in the same patient, the aortic arch is distinguished from its branches (arrow heads).

e-Coronal planes of the chest and abdomen in a fetus with left atrial isomerism and interrupted inferior vena cava showing the azygos vein (AzV) running parallel and posterior to the descending aorta (on both sides of the spine).

f- Fetopathological examination showing azygos and aorta.

atrial appendages are therefore more accurate. [10]. Left atrial isomerism syndrome is usually observed in patients with bilateral left sidedness. Other common findings are left azygos continuation of the inferior vena cava, gastrointestinal malrotation, biliary atresia and absence of the gallbladder and abnormal cardiac or stomach position. [27,28].

Abbreviations

A, apex of the heart; AO, aorta; AZ, azygos vein; CS, coronary sinus; DV, ductus venosus; LHV, left hepatic vein; LSVC, left superior vena cava; PLSVC, persistent left superior vena cava; PV, portal vein; PVs: pulmonary veins; RA, right atrium; RSVC, right superior vena cava; SVC, superior, S : spine. St: stomach. T, thorax; UV, umbilical vein. VCI, IVC: inferior vena cava. HV: Hepatic vein.

Absence of the hepatic segment portion of the IVC with azygos continuation into the right or left SVC is referred to as an interrupted IVC and it have been reported as an incidental finding at autopsy as early as 1793 by Abernethy in a 10-month-old infant with polysplenia and dextrocardia. Moller et al [18] emphasized the association, [11] and now it is considered an excellent marker for the presence of left atrial isomerism. a finding that occurs in about 80%. Therefore, a careful examination of the IVC should be performed in the suspected heterotaxy patient. [24,28]. In this condition, the venous drainage from the lower extremities reaches the superior vena cava via the azygos vein (azygos continuation) or via the hemiazygos vein (hemiazygos continuation) emptying into either a right-sided superior vena cava or into a persistent left superior vena cava. It can be recognized by the observation of the aorta and the (dilated) azygos vein on its right or left side (hemiazygos) either in the upper abdomen or at the level of the four-chamber view [31]. Sheley et al [29] described it as the 'double-vessel sign' (fig.3) and found it in all eight fetuses with left isomerism that they examined, but also in one false-positive case with right isomerism. If the examiner is aware of this sign, he can easily detect it prenatally on real-time imaging and confirm it using color Doppler. Three of our patients presented this sign (figure 3), care should be taken not to confound it with other conditions that mimic a 'double-vessel sign', for example,

esophageal duplication cyst, that can be confound with a dilated azygos vein in 4 chamber view, color doppler can differentiate between the two conditions. (figure 3 d, f).

Bilateral superior vena cava (SVC) occurs in about 41 % of cases of left atrial Isomerism and in 36 % cases of asplenia or right atrial Isomerism. [11] A (PLSVC) was diagnosed in two patients, with 3D ultrasound and Doppler, we have been able to reconstruct the 3D anatomy of the persistent left superior vena cava draining into the dilated coronary sinus and to the right atrium (figure 4b); moreover, reconstructing the 3-vessel view, a fourth vessel (PLSVC) is seen on the left side of the pulmonary artery. (Figure 4a).). In left atrial isomerism, multiple spleens, from 2 to 16, can be found, usually along the greater curvature of the stomach. [12]. Anomalies of midgut derivatives include nonrotation, incomplete rotation, and the rare reversed complete or incomplete rotation. [30]

One of our patients had nonrotation with the entire small bowel localizing to the right abdomen and colon localizing to the left abdomen and another patient had incomplete rotation), appendix and gall bladder (*white asterisk*) are on the left side, rectosigmoid is on the right side. (figure 1e, f)

A mismatch between the position of the fetal stomach and cardiac apex may be one of the first signs indicating atrial isomerism. [27]. 2 patients had the stomach in the right side, one of them without congenital heart disease. (figure 1 d, 3b).

In our previous work [31], we demonstrated that, in parasagittal view, both left hepatic vein (LHV) and the apex of the heart are in the same side and point to the same direction. Thus , the diagnosis of dextrocardia is achieved by Doppler imaging following localization of the apex of the heart and axis of the left hepatic vein, furthermore, in normal position (levocardia) the cardiac apex is oriented away from the spine (figure 2 a) , on the other hand, in dextrocardia, the cardiac apex is oriented toward the spine (Figure 2 d) , to the best of our knowledge , this the first study evoking the diagnosis of situs using these parameters (orientation of cardiac apex with regard to LHV and spine). Another example demonstrating the utility of this parasagittal view is shown in (figure 2 e, f), the LHV is

Table 1. Summary of patients

	Case 1	Case 2	Case 3	Case 4
Heart position	Dextrocardia	Levocardia	Levocardia	Levocardia
Stomach	Left	Right	Right	Left
IVC	Interruption	Interruption	No	Interruption
Interruption of IVC with azygos continuation	Yes	Yes	Yes	Yes
Cardiac malformations	AVC- Single atrium (SA) Anomalous hepatic venous drainage directly into the right atrium	LPSVC	AVC Aortic coarctation LPSVC	Aortic arche hypoplasia Single ventricle
Digestive anomalies	Midline liver Polysplenia. Intestinal malrotation Appendix on the right side	Midline liver	Midline liver Intestinal nonrotation	Midline liver duodenal obstruction from Ladd bands,
Caryotype	46XX	46XY	46XY	46XX
Outcome	Pregnancy termination	Delivery at 27+6 weeks	Pregnancy Termination	Pregnancy Termination

AVC: Atrioventricular canal, IVC: Inferior vena cava, SVC: Superior vena cava, PLSVC: Persistent left Superior vena cava, UV : Umbilical vein, SA: Single Atrium.

pointing in the opposite direction to the cardiac apex i.e. upwards toward the thorax, a diagnostic clue to diaphragmatic hernia, in this case the diagnosis was confirmed by fetopathological examination. In addition, Grayscale facilitated the diagnosis of situs and confirmed the diagnosis of dextrocardia and right-sided stomach and midline position of the liver (figure1).

Any deviation from this standard anatomic position (cardiac apex and LHV are in the same side and point to the same direction i.e. downwards on the other hand cardiac apex points in an opposite direction from the spine), using either Glass body mode or power Doppler or Doppler angiography or grayscale would be necessities further evaluation. For example, (Figure 2 d) the cardiac apex and the LHV are in opposite directions and the cardiac apex points toward the spine, denoting an abnormal cardiac axis (Dextrocardia), thus using this parasagittal view, it is possible to diagnose this abnormality using either Doppler angiography with or without glass body mode.

Conclusion

Left atrial isomerism is diagnostically challenging due to complex spectrum of findings. To our knowledge, this is the first study in which atrial isomerism is evoked based on study of the cardiac apex, the LHV and assessment of the vena cava (IVC) in parasagittal view. In structurally normal heart with levocardia, with presence of a normal IVC and a right sided stomach, the chances of having left isomerism would be very low. We believe that parasagittal view demonstrating the heart and the abdominal vessels is easy to obtain and interpret, offer a realistic anatomic image, needs no mental reconstruction of spatial relationships and is very beneficial mainly in detecting the situs and provides an added tool for the diagnosis of other anomalies and we propose to obtain this view, if not routinely, in all cases suspected of situs anomalies. We recommend to use 3D ultrasound and doppler angiography systematically in suspected cases of left atrial isomerism, and better understand and interpret fetal anatomy.

Conflict of Interest

The authors have no conflicts of interest.

References.

1. Daniel T. Grimes. Making and breaking symmetry in development, growth and disease *Development* 146, dev170985. doi:10.1242/dev.170985. 2019
2. Karen Koefoed Iben Rønn Veland, Lotte Bang Pedersen Lars Allan Larsen, and Søren Tvorup Christensen, Cilia and coordination of signaling networks during heart development. *Organogenesis* 10:1, 108–125; 2014
3. Chen, Q., Shi, J., Tao, Y., & Zernicka-Goetz, M. Tracing the origin of heterogeneity and symmetry breaking in the early mammalian embryo. *Nature Communications*, 9(1), 1819. 2018.
4. Liu, S., Chen, W., Zhan, Y. *et al.* *DNAH11* variants and its association with congenital heart disease and heterotaxy syndrome. *Sci Rep* 9, 6683 (2019). <https://doi.org/10.1038/s41598-019-43109-6>
5. Onoufriadis A, Paff T, Antony D, Shoemark A, Micha D, Kuyt B, Schmidts M, Petridi S, Dankert-Roelse JE, Haarman EG, et al. UK10K Splice-site mutations in the axonemal outer dynein arm docking complex gene *CCDC114* cause primary ciliary dyskinesia. *Am J Hum Genet.* 2013;92:88–98. doi: 10.1016/j.ajhg.2012.11.002
6. Deepak Babu and Sudipto Roy, Left-right asymmetry: cilia stir up new surprises in the node. *Open Biol.* 2013 3, 130052.
7. Jacobs JP, Anderson RH, Weinberg PM, et al. The nomenclature, definition and classification of cardiac structures in the setting of heterotaxy. *Cardiol Young* 2007; 17:1–28.
8. Alper Dilli, Salih Sinan Gultekin, Umit Yasar Ayaz, Hatice Kaplanoglu, and Baki Hekimoglu. A Rare Variation of the Left atrial isomerism Case Reports in *Medicine* Volume 2012 (2012), Article ID 840453, doi.org/10.1155/2012/840453.
9. Lagrotta, Gustavo, and Melanie Moises. "Heterotaxy Polysplenia Syndrome in Adulthood: Focused Review and a Case Report." *Cureus* vol. 12,1 e6822. 30 Jan. 2020, doi:10.7759/cureus.6822
10. Ryerson LM, Pharis S, Pockett C, et al. Left atrial isomerism and Intestinal Rotation Abnormalities.

- Pediatrics. 2018;142(2): e20174267
11. MDPI and ACS Style. Ilian, A.; Motoc, A.; Balulescu, L.; Secosan, C.; Grigoras, D.; Pirtea, L. A Case Report of Left Atrial Isomerism in a Syndromic Context. *Genes* 2020, 11, 1211.
 12. Patrick W. O'leary, Donald J. Hagler. Cardiac Malpositions and Abnormalities of Atrial and Visceral Situs, In: David J. Driscoll, Robert E. Shaddy, Timothy F. Feltes, editors, *Moss and Adams' Heart Disease in Infants, Children, and Adolescents*, 8th Ed Lippincott Williams & Wilkins, 2012; 53: 1195-1216.
 13. Caren Meneghetti Gonçalves et al, Heterotaxy syndrome: a case report, *Radiol Bras.* 2014 Jan/Fev;47(1):54–56
 14. El Guindi, W., Dreyfus, M., Carles, G., Lambert, V., Herlicoviez, M. and Benoist, G. (2013), 3D ultrasound and Doppler angiography for evaluation of fetal cardiovascular anomalies. *International Journal of Gynecology & Obstetrics*, 120: 173-177. doi:10.1016/j.ijgo.2012.08.015
 15. Smita Mishra, Seema Thakur. Heterotaxy syndrome. In: I. B. Vijayalakshmi, P. Syamasundar Rao, Reema Chugh *A Comprehensive Approach to Congenital Heart Diseases*; 10; p 145-165, JP Medical Ltd, 2013.
 16. Ivemark BI. Implications of agenesis of the spleen on the pathogenesis of conotruncus anomalies in childhood. *Acta Paediatr* 1955; 44(Suppl 104): 7–110.
 17. Polhemus DW, Schafer WB (1952) Congenital absence of the spleen; syndrome with atrioventricularis and situs inversus; case reports and review of the literature. *Pediatrics* 9:696–708.
 18. Moller IH, Nakib A. Anderson RC. Edwards JE. Congenital cardiac disease associated with polysplenia. A developmental complex of bilateral "left-sidedness." *Circulation* 1967;36:789-99.
 19. Van Mierop LHS. Wigglesworth FW. Isomerism of the cardiac atria in the asplenia syndrome. *Lab Invest* 1962;11:1303-15.
 20. Van Mierop LHS, Gessner IH, Schiebler GL. Asplenia and polysplenia syndrome. *Birth Defects: Original Article Series* 1972;1:74-82.
 21. Robert H. Anderson, Edward J. Baker, Daniel J. Penny, Andrew N. Redington, Michael L. Rigby, and Gil Wernovsky. *Paediatric cardiology*, Copyright 2010 by Churchill Livingstone, an imprint of Elsevier Ltd., Philadelphia, PA 19103-2899, Steven A. Webber, Hideki Uemura, and Robert H. Anderson, Isomerism of the Atrial Appendages :22;460-483.
 22. Van Praagh S, Kreuzer J, Alday L et al (1990) Systemic and pulmonary venous connections in visceral heterotaxy, with emphasis on the diagnosis of the atrial situs:a study of 109 postmortem cases. In: Clark EB, Takao A (eds) *Developmental cardiology. Morphogenesis and function*. Futura, Mount Kisco, pp 671–727
 23. Soto B, Pacifico AD. *Angiocardiography in Congenital Heart Malformations*. Mount Kisco, NY: Futura, 1990.
 24. Robert M. Freedom, Shi-Joon Yoo, Haverj Mikailian and William G. Williams : *The Natural and Modified History of Congenital Heart Disease*; Thomas Gilliam, Robert M. Freedom, and Shi-Joon Yoo, *The Syndrome of Isomeric Left Atrial Appendages, Often Associated with Polysplenia*, 34; 430- 434; 2004 by Futura, an imprint of Blackwell Publishing.
 25. Macartney FJ, Zuberbuhler JR, Anderson RH (1980) Morphological considerations pertaining to recognition of atrial isomerism. Consequences for sequential chamber localisation. *Brit Heart J* 44: 657–667
 26. Uemura H, Ho SY, Devine WA, et al. Atrial appendages and venoatrial connections in hearts from patients with visceral heterotaxy. *Ann Thorac Surg* 1995;60:561–569.
 27. Thomas C, Sawyer SN. Prenatal Findings in Left Atrial Isomerism and an Overview of Heterotaxy Syndrome. *Journal of Diagnostic Medical Sonography*. 2018; 34(2): 148-154. doi:10.1177/8756479317743196
 28. Agarwal, R., Varghese, R., Jesudian, V. et al. The heterotaxy syndrome: associated congenital heart defects and management. *Indian J Thorac Cardiovasc Surg* (2020). <https://doi.org/10.1007/s12055-020-00935-y>

29. Sheley RC , Nyberg DA , Kapur R . Azygous continuation of the interrupted inferior vena cava: a clue to prenatal diagnosis of the cardiosplenic syndromes. *J Ultrasound Med* 1995; 14 : 381 – 7 .
30. Agarwal P, Agarwal RK. Left atrial isomerism associated with aneurysmal enlargement of right atrial appendage: A case report with literature review. *Indian J Radiol Imaging*. 2019;29(3): 318-323. doi:10.4103/ijri.IJRI_341_19
31. El Guindi W, Dreyfus M, Carles G, Lambert V, Herlicoviez M, Benoist G. 3D ultrasound and Doppler angiography for evaluation of fetal cardiovascular anomalies. *Int J Gynaecol Obstet*. 2013 Feb;120 (2):173-7. doi: 10.1016/j.ijgo.2012.08.015. Epub 2012 Nov 11. PMID: 23151371.